

Michael Johnston
Intensive Care Unit
Royal Bolton Hospital
Minerva Road
Bolton
BL40JR

michael.johnston678@gmail.com

A novel percutaneous tracheostomy technique to reduce aerosolisation during the COVID-19 pandemic: a description and case series

Michael Johnston¹, Michael Weldon², Chloe Smart², Clifford Shelton^{3,4}, Ajmal Eusuf²

¹North Western School of Anaesthesia, Manchester, UK

²Intensive Care Unit, Royal Bolton Hospital, Bolton, UK

³Department of Anaesthesia, Wythenshawe Hospital, Manchester University NHS Foundation Trust, Manchester, UK

⁴Lancaster Medical School, Faculty of Health and Medicine, Lancaster University, Lancaster, UK

Declaration of Interests

The authors declare no funding and no conflicts of interest.

Key Words

Pandemics

Tracheostomy

Infection Control

Patient Safety

Airway Management

Novel dilatational percutaneous tracheostomy technique to reduce aerosolisation during the COVID-19 pandemic: a description and case series

Abstract

Background

COVID-19 is a global pandemic with many patients requiring prolonged mechanical ventilation. COVID-19 is associated with laryngeal oedema and a high rate of reintubation and difficult airway. Tracheostomy insertion is an aerosol generating procedure, so we strived to make our novel technique safe for operator and patient.

Aim

To share our experience of a novel percutaneous tracheostomy technique, based on a case series of 18 patients with COVID-19 pneumonitis.

Method

Our novel percutaneous tracheostomy technique is a landmark-based approach without bronchoscopic confirmation of the correct needle placement. Blunt dissection using tracheal dilators onto the tracheal rings facilitates first pass needle insertion into the trachea. The tracheal tube is retracted into the supraglottic airway, the cuff overinflated, and a wet throat pack inserted to reduce aerosolisation.

Results

From March 2020 to May 2020, 38 patients with suspected or confirmed COVID-19 presented to Royal Bolton Hospital requiring invasive ventilation. 18 patients underwent percutaneous tracheostomy. 6 patients have been decannulated, 12 patients died. Mean time from intubation to tracheostomy was 6.1 days and from tracheostomy to decannulation 20.6 days. No operator developed COVID-19 symptoms.

Conclusions

Despite the low numbers our novel technique appears to be safe, but confirmation requires a larger controlled trial. As an institution we have avoided difficulties with reintubation and reduced our drug usage.

Introduction

The COVID-19 pandemic has placed critical care units under extraordinary pressure, with an unprecedented number of patients requiring prolonged tracheal intubation and mechanical ventilation for respiratory failure. It has been observed that COVID-19 appears to be associated with a high rate of re-intubation due to laryngeal oedema, and this also may confer a risk of difficult airway [1]. Furthermore, many critical care units have reported being on the verge of being overwhelmed, either in terms of physical space, or the availability of medical gases, equipment, and drugs. When used appropriately, tracheostomy mitigates the risk of failed tracheal extubation and reduces the need for scarce resources such as sedative medication. However, tracheostomy insertion is classified as an aerosol generating procedure, and therefore may confer an increased risk of SARS-CoV-2 transmission to staff as a consequence of exposure to aerosolised viral material [2]. A number of approaches exist to minimise the risk of aerosol generating procedures; these include the appropriate use of personal protective equipment (PPE), conducting procedures in an appropriately ventilated space, and minimising the number of such procedures undertaken. There is also scope to modify procedures so that the quantity or duration of aerosol exposure is reduced. In this paper we report the novel approach to percutaneous tracheostomy that we developed at Royal Bolton Hospital, UK, in order to enable the timely performance of tracheostomy for patients with COVID-19 whilst minimising risk to staff and patients.

Percutaneous tracheostomy for patients with COVID-19

The National Tracheostomy Safety Project (NTSP) provided consensus-based recommendations for tracheostomy in patients with COVID-19, in collaboration with the Royal College of Anaesthetists, Faculty of Intensive Care Medicine, ENT-UK and the Difficult Airway Society [3]. This document advocated an open tracheostomy technique, which although not confined to a theatre setting, is difficult to do on the intensive care unit. Regarding percutaneous tracheostomy insertion, the NTSP document states that this procedure risks the leakage of exhaled gases and hence exposure to aerosols, although it is acknowledged that this risk could be mitigated with packing of the hypopharynx. Another concern with the standard percutaneous tracheostomy approach is that bronchoscopy is also stated to be an aerosol generating procedure [2].

The Critical Care and Acute Care Surgery Committees of the American Association for the Surgery of Trauma has published guidance on performing percutaneous tracheostomies without bronchoscopy [4]. To compensate for the loss of visual guidance, they advise palpating the trachea, noting an increase in tracheal compliance as the tracheal tube is withdrawn, therefore enabling avoidance of tracheal tube cuff perforation. However, this technique requires a significant amount of operator experience to perform as the rigidity of trachea is a subjective measure.

Takhar et al describe a technique to withdraw the tracheal tube using direct laryngoscopy without the use of bronchoscopy [5]. However, the use of direct laryngoscopy is discouraged in the consensus guidelines on airway management in COVID-19 as it is felt to confer a significant risk of aerosol exposure to the operator [6].

A novel method is proposed by Angel et al., involving the insertion of a bronchoscope alongside to the tracheal tube [7]. Following bronchoscope insertion, ventilation is paused, the tracheal tube cuff is deflated, and the tracheal tube advanced distally before cuff reinflation to provide anatomical space for percutaneous tracheostomy insertion. Angel et al. found that suction was required in the oropharynx to allow adequate visualisation with bronchoscope, which again is a potential aerosol generating procedure [2]. Angel et al. also identified two cases out of their series of 98 patients, who had laryngeal oedema of such an extent that the bronchoscope could not be advanced adjacent to the tracheal tube [7].

Several other authors have advocated the use of drapes or barrier enclosures to block exposure to aerosols during tracheostomy procedures [8,9]. Though these may confer some benefits, they remain untested and have the capacity to obstruct the operator, damage personal protective equipment, and restrict access to the patient should an emergency occur [10-12].

McGrath et al convened an international consensus working group to establish guidelines on tracheostomy insertion in the COVID-19 era [13]. They advise delaying tracheostomy insertion until at least day 10 of mechanical ventilation, in order to allow time for the patient's viral load to fall, thereby reducing the risk to staff, should exposure to aerosolised respiratory secretions occur.

Drawing on the above literature, we developed a pragmatic technique for early percutaneous tracheostomy, which could be safely performed by critical care clinicians within the intensive care unit, to facilitate weaning from ventilatory support and sedation, in patients with COVID-19.

Methods

The Health Research Authority decision tool (hra-decisiontools.org.uk) was used to confirm that this case series was considered a service evaluation; formal ethical approval was therefore not sought. However, institutional approval for retrospective data collection was granted and the principles of Good Clinical Practice were observed.

All patients with polymerase chain reaction (PCR) confirmed SARS-CoV-2 infection admitted to the intensive care unit at Royal Bolton Hospital with respiratory failure requiring invasive mechanical ventilation between 16th March and April 27th 2020 are included in this case series. One patient who had typical clinical features of COVID-19 but repeatedly tested negative on SARS-CoV-2 PCR is also included.

In view of the extraordinary clinical demand, the generally accepted criteria for performing percutaneous tracheostomy such as FiO₂ of under 0.6 and positive end expiratory pressure (PEEP) of less than 12cm H₂O were not used. We did not specify any requirements in terms of ventilator settings, only that patients must have failed a sedation hold and that the decision for tracheostomy should have been made by consensus of the multidisciplinary team. Any coagulopathy was corrected, and low molecular weight heparin was held for 12 hours prior to the procedure. Patients' next of kin provided verbal consent via telephone. Data on tracheostomy complications, decannulation rate, and patient outcome were collected retrospectively from patients' medical notes.

Percutaneous tracheostomy technique

Multiple techniques of percutaneous tracheostomy insertion have been described [14]. The most used technique in the United Kingdom is the single tapered dilator technique [15]. Whilst practice varies between intensive care units, we derived our novel approach from the Ciaglia Blue Rhino (Cook Critical Care, Bloomington, USA) technique, which is most commonly used in our institution [16].

As no side rooms were available, all percutaneous tracheostomies were performed in the open ward area of the intensive care unit with all personnel wearing 'airborne' PPE, comprising a fit-tested filtering face piece 3 (FFP3) mask, visor, surgical hat, fluid repellent gown and two pairs of gloves. None of our percutaneous tracheostomy were performed in the operating theatre. Although the procedure was performed in the open ward, staff numbers at the bedside were minimised. The 'B@EASE' ICU percutaneous tracheostomy Insertion checklist was used prior to procedure; we did not modify this checklist to specifically account for our novel percutaneous tracheostomy technique [17].

A major difference in our technique is that bronchoscopy is not used to confirm correct tracheostomy tube placement and position. The most senior clinician conducted both the oral airway management and the percutaneous tracheostomy. The majority of percutaneous tracheostomies were performed by intensive care consultants, one by a senior anaesthetic trainee and the remainder were performed by an Ear Nose and Throat (ENT) surgeon; all operators used the same technique (Figure 1 and 2).

1. Increase FiO₂ to 1.0.
2. Ensure adequate sedation; administer neuromuscular blocking agent and confirm effect with neuromuscular monitoring.
3. Aspirate nasogastric tube.
4. Standard positioning for percutaneous tracheostomy, with neck extension

5. 'Oral airway' doctor inserts fingers through the patient's mouth to epiglottis.
6. Ventilation is paused.
7. The tracheal tube cuff is then deflated, then the tube is retracted by feel until the cuff is above the glottis.
8. The tracheal tube cuff is overinflated to act as a supraglottic seal, with the tip of the tracheal tube still in the trachea.
9. A wet throat pack is inserted into hypopharynx, above the tube cuff.
10. Ventilation is restarted.
11. Chlorhexidine 2% applied to skin; 20ml of 1-2% lidocaine with adrenaline 1:200,000 infiltrated dermally and subcutaneously.
12. Fenestrated drape applied.
13. 1cm horizontal midline neck incision made.
14. Tracheal dilators used for blunt dissection until tracheal rings palpated or visualised.
15. Ventilator paused.
16. Insertion of needle and usual sequence of dilatation and tracheostomy tube insertion.
17. Tracheostomy tube cuff inflated.
18. Circuit with closed circuit suction attached.
19. Ventilation is restarted.
20. Confirmation of correct placement via capnography and auscultation.

Figure 1: steps of the novel technique for percutaneous tracheostomy

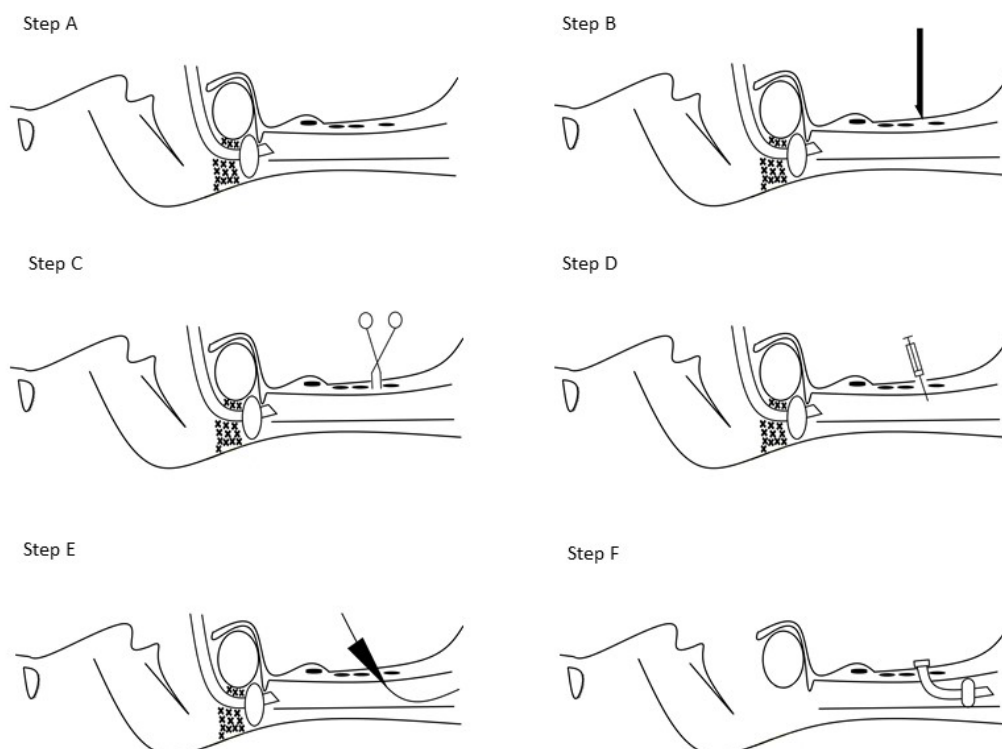


Figure 2: Illustration of the key steps of the novel percutaneous tracheostomy technique. **A:** Tracheal tube in “supraglottic position” with throat pack in situ. **B:** 1cm horizontal neck incision. **C:** Blunt dissection using tracheal dilators. **D:** Needle inserted into trachea under direct vision and palpation. **E:** Standard dilatation. **F:** Percutaneous tracheostomy cannula inserted.

If first-pass needle insertion into the trachea was unsuccessful, ventilation was recommenced until peripheral arterial oxygen saturations improved and the attempt was repeated. If capnography or chest rise was not observed, the tracheostomy would be removed and the tracheal tube cuff deflated, the tracheal tube would then be advanced and the cuff re-inflated, followed by recommencement of ventilation and repeat attempt at percutaneous tracheostomy re-attempted, if appropriate.

Results

From 16th March to 27th April 2020, 38 patients with suspected or confirmed COVID-19 presented to the Royal Bolton Hospital critical care unit requiring invasive ventilation. Percutaneous tracheostomy was performed on 18 patients (47%), of whom 17 had SARS-CoV-2 confirmed by PCR from nose and throat swabs or sputum samples, one patient had five negative swabs but a strong clinical suspicion of COVID-19. The mean time from tracheal intubation to percutaneous tracheostomy was 6.1 days (SD 3.2). Five procedures were performed by a consultant ENT surgeon, 12 by intensive care consultants and one by a senior anaesthetic trainee.

One major complication occurred: a pneumothorax identified immediately post tracheostomy which was managed with chest drain insertion. Three patients developed a cuff leak during their prolonged respiratory wean, due to physical damage to the tracheostomy cuff, which was resolved by changing the tracheostomy tube. Two patients had prolonged bleeding around the tracheostomy site, which was managed conservatively and led to no significant clinical issues. Of note, our approach was to administer anticoagulation with treatment dose low molecular weight heparin and aspirin to all patients with COVID-19.

Following percutaneous tracheostomy, it took a mean of 3.6 days (SD 2.0) to wean completely from intravenous sedation. For all patients who were decannulated (n=6), this was successful on the first attempt; the mean time from percutaneous tracheostomy procedure to decannulation was 20.6 days (SD 10.3). At the time of writing no patients remain mechanically ventilated, eight have been decannulated. Of these, five have been discharged home, one patient remains an inpatient within the hospital, and two patients died. Ten patients died with the tracheostomy still in-situ.

None of the 12 clinicians involved in the percutaneous tracheostomy procedure have displayed symptoms of COVID-19, reported testing positive for SARS-CoV-2, or been required to isolate.

Table 1. Patient Demographics

Gender	
Male	10
Female	8
Age	
Mean (years)	55.1 ± 8.3
Range (years)	38 - 69
Weight	
Mean (kg)	83.7 ± 13.8
Range (kg)	58.5 - 102
Height	
Mean (cm)	168.5 ± 12.7
Range (cm)	150 - 190

BMI	
Mean	29.7 ± 5.6
Range	23.3 - 37.3
Comorbidities	
Hypertension	7
Diabetes	12
Asthma	5
FiO₂ at time of percutaneous tracheostomy	
Mean	0.65 ± 0.15
Range	0.44 - 0.90
PEEP at time of percutaneous tracheostomy	
Mean (cm/ H ₂ O)	9.9 ± 1.8
Range (cm / H ₂ O)	7 - 15
Ethnicity	
White	12
Asian	5
Black	1

Table 2. Results

ICU admissions with Covid-19 (16/3/2020 to 27/4/2020)	
Patients mechanically ventilated with suspected/ confirmed COVID-19	38
Number of patients who underwent percutaneous tracheostomy	18
Outcome following percutaneous tracheostomy (n=18)	
Discharged Home	6
Died	12
Days from intubation to percutaneous tracheostomy (n=18)	
Mean	6.1 ± 3.2

Range	2-13
Days from percutaneous tracheostomy to decannulation (n=6)	
Mean	20.6 ± 10.3
Range	9 - 34
Days from tracheostomy to death (n=12)	
Mean	9 ± 3.7
Range	5 - 16
Patient complications	
Pneumothorax	1
Bleeding (minor)	2
Cuff leak requiring tracheostomy change	3
Days from percutaneous tracheostomy to weaning from intravenous to enteral sedation (n=6)	
Mean	3.6 +/- 2.4
Range	1 - 7
Operators becoming symptomatic for Covid-19 (n=12)	
Operators becoming symptomatic	0

Discussion

Our proposed novel percutaneous tracheostomy technique appears to represent a safe procedure for both operators and patients. Though there were however a small number of patient complications, and it is possible that bronchoscopic guidance may have reduced the risk of these, we made the decision to avoid this to reduce the potential for operator exposure to aerosolised viral material; a logical approach to preserving staff welfare and critical care capacity in the midst of a pandemic.

The pneumothorax that occurred was the only significant complication and this was identified and managed immediately post procedure. Pneumothorax is the most frequent complication following percutaneous tracheostomy with an incidence of up to 17% reported in some studies [14]. Although our study is small, the single case of pneumothorax represents 5.6% of our series, which appears to be consistent with the findings of other authors [14].

Two patients had bleeding around the percutaneous tracheostomy site, which was clinically insignificant and had no effect on outcome. The bleeding was likely related to our decision to anticoagulate patients with treatment dose low molecular weight heparin and aspirin due to the prothrombotic nature of COVID-19. The cuff leaks all occurred significantly after the date of percutaneous tracheostomy and the tracheostomy tube change was uneventful in all cases.

Our approach was developed using the techniques with which our team were most experienced and comfortable. Modifications of the approach could involve the use of video laryngoscopy to observe the withdrawal of the tracheal tube, rather than digital palpation [18,19]. However, we feel that direct laryngoscopy, which exposes the operator to the airway at minimal distance is not appropriate [6].

We opted for early percutaneous tracheostomy (performed at mean 6.1 days post mechanical ventilation) which confers certain benefits, particularly in the context of the COVID-19 pandemic. We avoided any issues related to difficult reintubation and airway oedema which has been reported at other institutions. Mortality and morbidity is increased with reintubation in the general critical care patient population, and it seems reasonable this would be the case for patients with COVID-19 although there is no evidence to confirm or refute this [20]. One issue with early percutaneous tracheostomy has been the technical challenge of transferring these patients to the prone position. This has been manageable, but it is more challenging than doing so with a tracheal tube, due to being unable to visualise the tracheostomy and the concomitant risk of pressure damage.

As a result of performing early tracheostomy, we were able to reduce our use of drugs including sedatives, neuromuscular blocking agents, vasopressors and oxygen, which is beneficial at a time of resource limitation [21]. Recovering patients who have had sedation weaned can potentially be managed in lower acuity areas, increasing capacity for more unwell patients.

An international tracheostomy consensus working group has suggested tracheostomy should be delayed until at least day 10 of mechanical ventilation and when patient is improving clinically [13]. This guidance was published following completion of our case series. Many other institutions have opted for delayed tracheostomies at day 14-21 following tracheal intubation, or after negative SARS-CoV-2 PCR testing to reduce operator infection risk due to viral shedding. No operator became symptomatic of COVID-19 in our case series, which suggests that delayed tracheostomy may not be necessary and that by delaying, an opportunity is missed to obtain the above benefits; although we recognise that operators were unable to be regularly tested in our institution.

Early evidence indicates that in critically unwell patients with COVID-19, viral shedding occurs beyond 21 days, with one study showing a median duration of viral shedding of 31 days from illness onset [22]. Another study showed lower respiratory tract samples remain PCR positive for Covid-19 up to 39 days after upper respiratory tract samples had become negative [23]. If this is the case, then delaying percutaneous tracheostomy would reduce the benefits we have discussed and potentially still expose the operators to a significant viral load.

Our case series raises several questions for further investigation. Firstly, does bronchoscopy actually make tracheostomy safer or confer any benefit to patients? Secondly, which technique is best for tracheostomy; surgical; hybrid or percutaneous tracheostomy? And finally, an analysis of all tracheostomies performed during the COVID-19 pandemic would be of great interest as it is possible that bronchoscopy is safe for the operator providing PPE is worn.

There are some weaknesses to our case series. The dataset is small and this limits the power of our conclusions. Furthermore, we have not been able to test operators for COVID-19 as part of the study, either utilising PCR or antibody tests, which would have given us a further indication about viral transmission. A large, controlled trial, including staff testing, would be required to definitively determine the safety and success of this technique

There are strengths to our technique: no healthcare professionals experienced symptoms post procedure, suggesting the safety of our approach for the operators and possibly the safety of early percutaneous tracheostomy in COVID-19 patients. The low complication rate suggests the technique is safe for use in patients. Blunt dissection down to the trachea minimises the time from needle puncture to tracheostomy insertion (around 30 seconds), meaning that an apnoea test was not required pre-procedure, and also that we were able to perform percutaneous tracheostomy in patients with higher oxygen and positive end expiratory pressure requirements.

The technique described may represent the “least worst” technique at an exceptionally challenging time and represents a pragmatic approach during the current pandemic. Further research particularly regarding timing of tracheostomy and the complications and safety of tracheostomy in patients with COVID-19 should be prioritised.

Conclusion

Despite the relatively low number in our case series, our novel technique appears to be safe for patients and staff, but confirmation requires a larger controlled trial. As an institution we have avoided difficulties with reintubation and reduced our drug usage, and therefore optimised the use of scarce resources at a time of extraordinary clinical demand.

References

1. McGrath BA, Wallace S, Goswamy J. Laryngeal oedema associated with COVID-19 complicating management. *Anaesthesia* 2020; 75: 792
2. Public Health England. COVID-19: Infection Prevention and Control, 2020, available at: <https://www.gov.uk/government/publications/wuhan-novel-coronavirus-infection-prevention-and-control> Accessed 15th July 2020
3. National Tracheostomy Safety Project. Multidisciplinary COVID-19 Tracheostomy Guidance, 2020, available from: http://www.tracheostomy.org.uk/storage/files/Multidisciplinary%20COVID_19%20tracheostomy%20guidance%2030_4_20.pdf Accessed 15th July 2020
4. Michetti CP, Burley CC, Bulger EM, Davis KA, Spain DA. Performing tracheostomy during the Covid-19 pandemic: guidance and recommendations from the Critical Care and Acute Care

- Surgery Committees of the American Association for the Surgery of Trauma. *Trauma Surgery and Acute Care Open* 2020; 5: e000482
5. Takhar A, Walker A, Tricklebank S, et al. Recommendation of a practical guideline for safe tracheostomy during the COVID-19 pandemic. *European Archives of Oto-Rhino-Laryngology* 2020; 277: 2173-84
 6. Cook TM, El-Boghdadly K, McGuire B, McNarry AF, Patel A, Higgs A. Consensus guidelines for managing the airway in patients with COVID-19. *Anaesthesia* 2020; 75: 785-99
 7. Angel L, Kon ZN, Chang SH, et al. Novel Percutaneous Tracheostomy for Critically Ill Patients With COVID-19. *Annals of Thoracic Surgery* 2020; DOI: 10.1016/j.athoracsur.2020.04.010
 8. Filho W, Teles T, da Fonesca M, et al. Barrier device prototype for open tracheostomy during COVID-19 pandemic. *Auris Nasus Larynx* 2020; DOI: 10.1016/j.anl.2020.05.003
 9. Prabhakaran K, Malcom R, Choi J, et al. Open tracheostomy for covid19 positive patients: a method to minimize aerosolization and reduce risk of exposure. *J Trauma Acute Care Surg.* 2020; doi: 10.1097/TA.0000000000002780
 10. Huda T, Alexander PDG, Shelton C, McGrath BA. Negative pressure hoods for COVID-19 tracheostomy: unanswered questions and the interpretation of zero numerators. *J Trauma Acute Care Surg* 2020; in press.
 11. Huda T, Alexander PDG, McGrath B, Shelton C. The COVID-Box for tracheostomy: Additional complexity and unanswered questions. *Auris Nasus Larynx* 2020; DOI: 10.1016/j.anl.2020.06.004.
 12. Gould C, Alexander P, Allen C et al. Protecting staff and patients during airway management in the COVID-19 pandemic: are intubation boxes safe?. *British Journal of Anaesthesia* 2020; doi: 10.1016/j.bja.2020.05.001
 13. McGrath BA, Brenner MJ, Warrillow SJ et al. Tracheostomy in the COVID-19 era: global and multidisciplinary guidance. *Lancet Respiratory Medicine* 2020; doi: 10.1016/S2213-2600(20)30230-7
 14. Cipriano A, Mao ML, Hon HH, Vazquez D, Stawicki SP, Sharpe RP, Evans DC. An overview of complications associated with open and percutaneous tracheostomy procedures. *International Journal of Critical Illness and Injury Science.* 2015; 5 :179-88
 15. Veenith T, Ganeshamoorthy S, Standley T, carter J, Young P. Intensive care unit tracheostomy: a snapshot of UK practice. *International Archives of Medicine* 2008; 1: 21
 16. Byhahn C, Lischke V, Halbig S, et al. Ciaglia Blue Rhino: a modified technique of percutaneous dilatational tracheostomy— technique and early results. *Anaesthetist* 2000; 49: 202–6
 17. National Tracheostomy Safety Project. BE@EASE ICU Tracheostomy Insertion Checklist, 2018, available from: <http://www.tracheostomy.org.uk/storage/files/B@EASE%20Trachy%20Checklist.pdf> Accessed 15th July 2020
 18. M. Gillies, J. Smith, C. Langrish, Positioning the tracheal tube during percutaneous tracheostomy: another use for videolaryngoscopy, *BJA: British Journal of Anaesthesia*, Volume 101, Issue 1, July 2008, Page 129, <https://doi.org/10.1093/bja/aen158>
 19. Karalapillai D, Darvall J, Mandeville J, Ellard L, Graham J, Weinberg L. A review of video laryngoscopes relevant to the intensive care unit. *Indian J Crit Care Med.* 2014 Jul;18(7):442-52. doi: 10.4103/0972-5229.136073. PMID: 25097357; PMCID: PMC4118510.
 20. Menon N, Joffe AM, Deem S, et al. Occurrence and complications of tracheal reintubation in critically ill adults. *Respir Care.* 2012;57(10):1555-1563.
 21. The Faculty of Intensive Care Medicine, UK Clinical Pharmacy Association, Intensive Care Society. Guidance on adaptations to standard UK critical care medication prescribing and administration practices during pandemic emergency pressures, 2020, available from:

<https://static1.squarespace.com/static/5e6613a1dc75b87df82b78e1/t/5e8612f80993e242651fbc86/1585844985693/Guidance-on-adaptations.pdf> Accessed 15th July 2020

22. Zhou B, She J, Wang Y, Ma X. Duration of Viral Shedding of Discharged Patients With Severe COVID-19. *Clinical Infectious Diseases* 2020; DOI: 10.1093/cid/ciaa451
23. Chen C, Gao G, Xu Y, et al. SARS-CoV-2–Positive Sputum and Feces After Conversion of Pharyngeal Samples in Patients With COVID-19. *Annals of Internal Medicine* 2020; DOI: 10.7326/M20-0991